A Multi-Modal Assessment of Melanin and Melanocyte Activity in Abnormally Pigmented Hypertrophic Scar

Taryn E. Travis, MD, Pejhman Ghassemi, PhD, Jessica C. Ramella-Roman, PhD, Nicholas J. Prindeze, BS, Dereck W. Paul, BS, Lauren T. Moffatt, PhD, Marion H. Jordan, MD, FACS, Jeffrey W. Shupp, MD

MedStar Washington Hospital Center

The Burn Center
MedStar Health

Firefighters' Burn and Surgical Research Laboratory

Disclosures

- No conflicts of interest

MedStar Washington Hospital Center
The Burn Center
MedStar Health

Firefighters' Burn and Surgical Research Laboratory

Abnormal Pigmentation

- Challenging to treat
- Distressing to patients
- Common in scar resulting from cutaneous trauma
- Less well-understood than normal skin pigmentation

MedStar Washington Hospital Center
The Burn Center
MedStar Health

Firefighters' Burn and Surgical Research Laboratory

Normal Pigmentation

- Function of melanocyte **activity**
  - Ratio of eumelanin to pheomelanin
  - Amount of melanin produced
- Not believed to be a function of melanocyte **quantity**

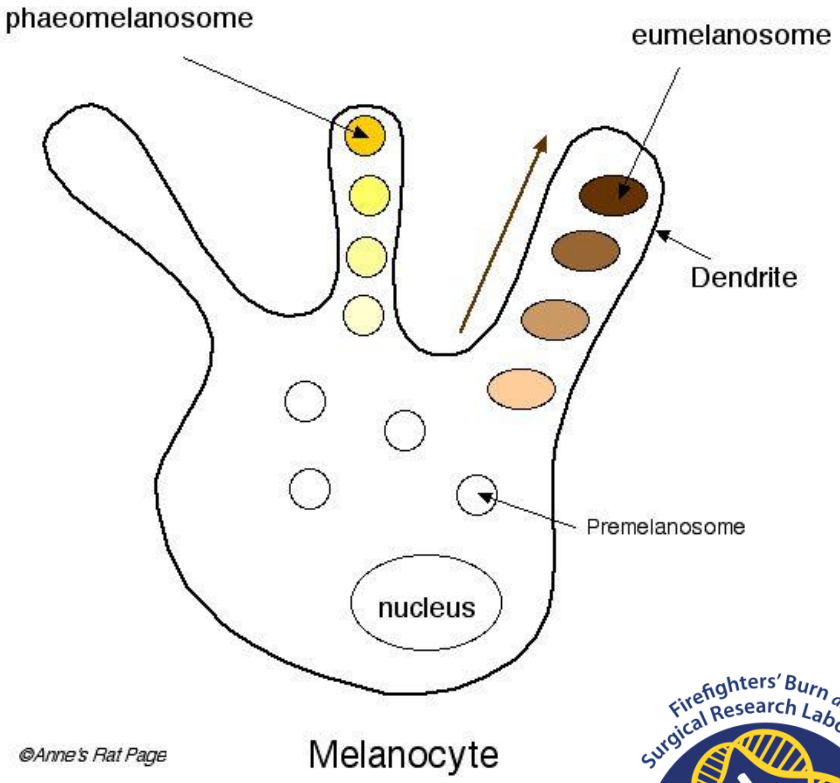

From: University of Bristol Palaeobiology and Biodiversity Research Group

MedStar Washington Hospital Center
The Burn Center
MedStar Health

Firefighters' Burn and Surgical Research Laboratory

Melanocytes

- Fusiform dendritic cells
- One melanocyte communicates with many keratinocytes
- Melanosomes are exported to nearby keratinocytes

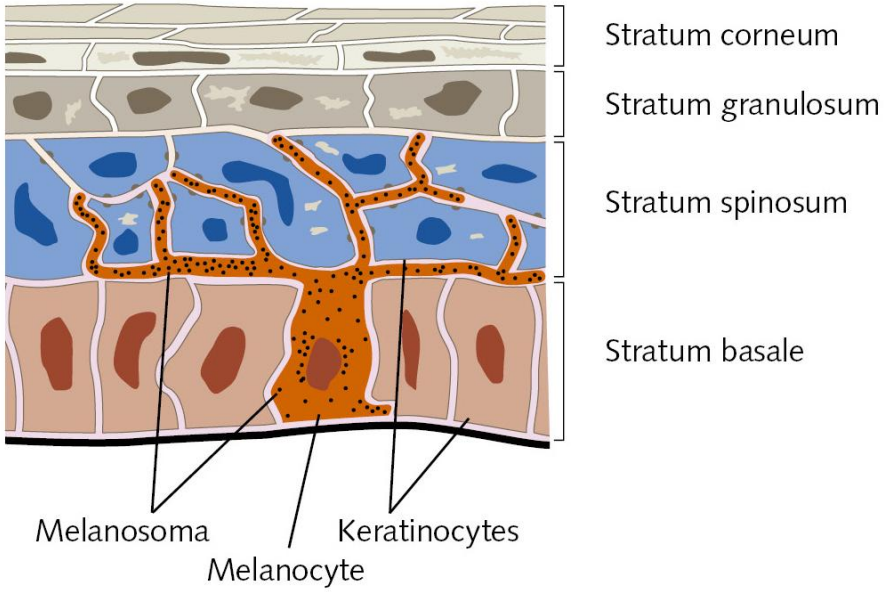

From: PromoCell

MedStar Washington Hospital Center
The Burn Center
MedStar Health

Firefighters' Burn and Surgical Research Laboratory

Duroc Swine

- Uniformly colored red-brown skin pre-injury
- Known to form scar
- Displays varying degrees of abnormal pigmentation in fibroproliferative scar

From: Kimball Stock

MedStar Washington Hospital Center
The Burn Center
MedStar Health

Firefighters' Burn and Surgical Research Laboratory

Experiment

Aims

- To evaluate the optical properties of melanin in abnormally pigmented scar

MedStar Washington Hospital Center
The Burn Center
MedStar Health

Firefighters' Burn and Surgical Research Laboratory

Experiment

Aims

- To evaluate the optical properties of melanin in abnormally pigmented scar
- To evaluate quantifiable differences in factors hypothesized to result in abnormal scar pigmentation

MedStar Washington Hospital Center

The Burn Center
MedStar Health

Firefighters' Burn and Surgical Research Laboratory

Experiment

Aims

- To evaluate the optical properties of melanin in abnormally pigmented scar
- To evaluate quantifiable differences in factors hypothesized to result in abnormal scar pigmentation

Methods

- Full thickness excisional wounds

MedStar Washington Hospital Center
The Burn Center
MedStar Health

Firefighters' Burn and Surgical Research Laboratory

Experiment

Aims

- To evaluate the optical properties of melanin in abnormally pigmented scar
- To evaluate quantifiable differences in factors hypothesized to result in abnormal scar pigmentation

Methods

- Full thickness excisional wounds
- Allowed to heal and scar

MedStar Washington Hospital Center
The Burn Center
MedStar Health

Firefighters' Burn and Surgical Research Laboratory

Experiment

Aims

- To evaluate the optical properties of melanin in abnormally pigmented scar
- To evaluate quantifiable differences in factors hypothesized to result in abnormal scar pigmentation

Methods

- Full thickness excisional wounds
- Allowed to heal and scar
- Evaluation for:
  - Melanocyte quantity
  - Melanocyte activity
  - Melanin content
  - Melanocyte stimulating hormone

MedStar Washington Hospital Center
The Burn Center
MedStar Health

Firefighters' Burn and Surgical Research Laboratory

Uninjured Duroc Skin

MedStar Washington Hospital Center

The Burn Center
MedStar Health

Firefighters' Burn and Surgical Research Laboratory

Day 14

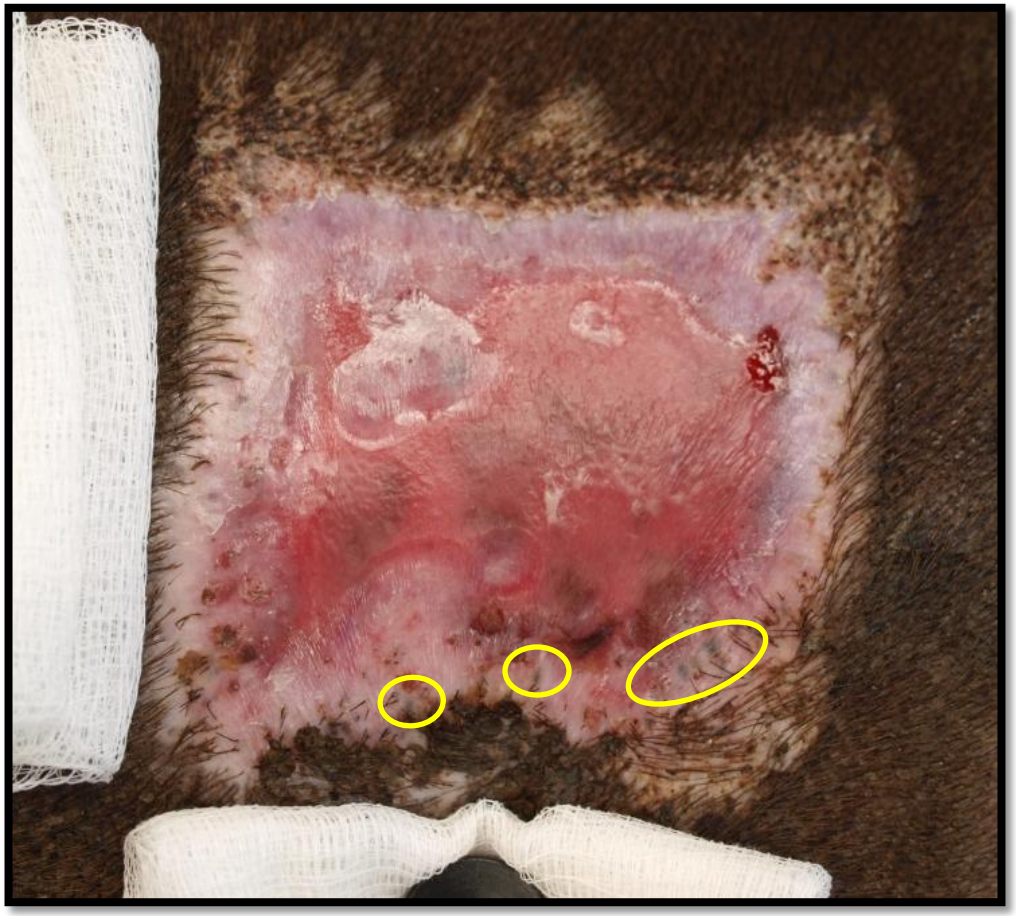

MedStar Washington Hospital Center

The Burn Center
MedStar Health

Firefighters' Burn and Surgical Research Laboratory

Day 49

MedStar Washington Hospital Center

The Burn Center
MedStar Health

Firefighters' Burn and Surgical Research Laboratory

Day 70

MedStar Washington Hospital Center

The Burn Center
MedStar Health

Firefighters' Burn and Surgical Research Laboratory

Day 91

MedStar Washington Hospital Center

The Burn Center
MedStar Health

Firefighters' Burn and Surgical Research Laboratory

Day 126

MedStar Washington Hospital Center

The Burn Center
MedStar Health

Firefighters' Burn and Surgical Research Laboratory

Day 126

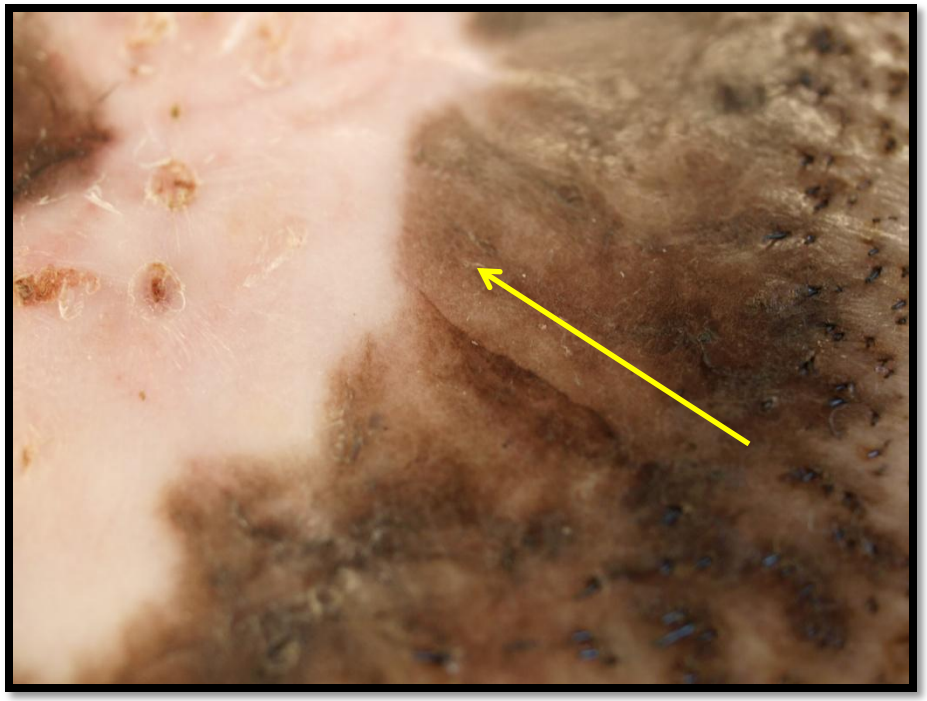

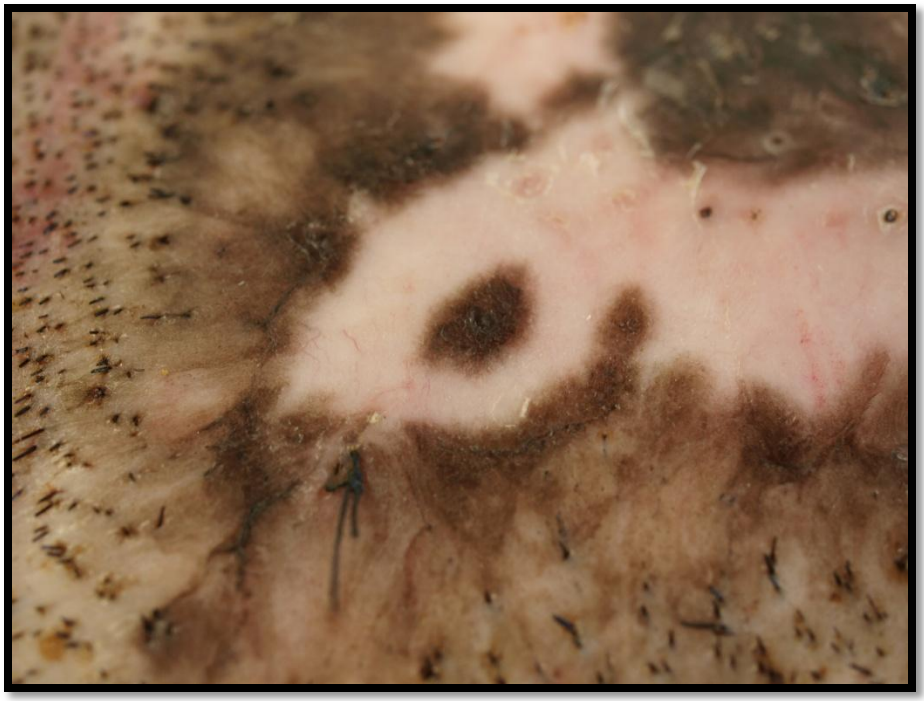

MedStar Washington Hospital Center
The Burn Center
MedStar Health

Firefighters' Burn and Surgical Research Laboratory

Spectral Imaging

- Spatial Frequency Domain Imaging
- Imaged the absorption and scattering coefficients of reepithelialized wounds

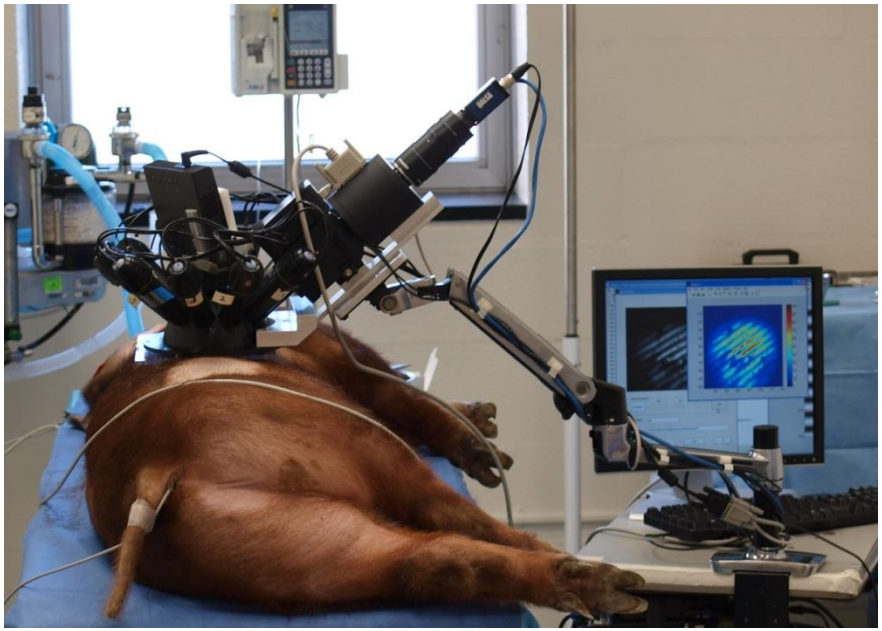

MedStar Washington Hospital Center
The Burn Center
MedStar Health

Firefighters' Burn and Surgical Research Laboratory

Spectral Imaging

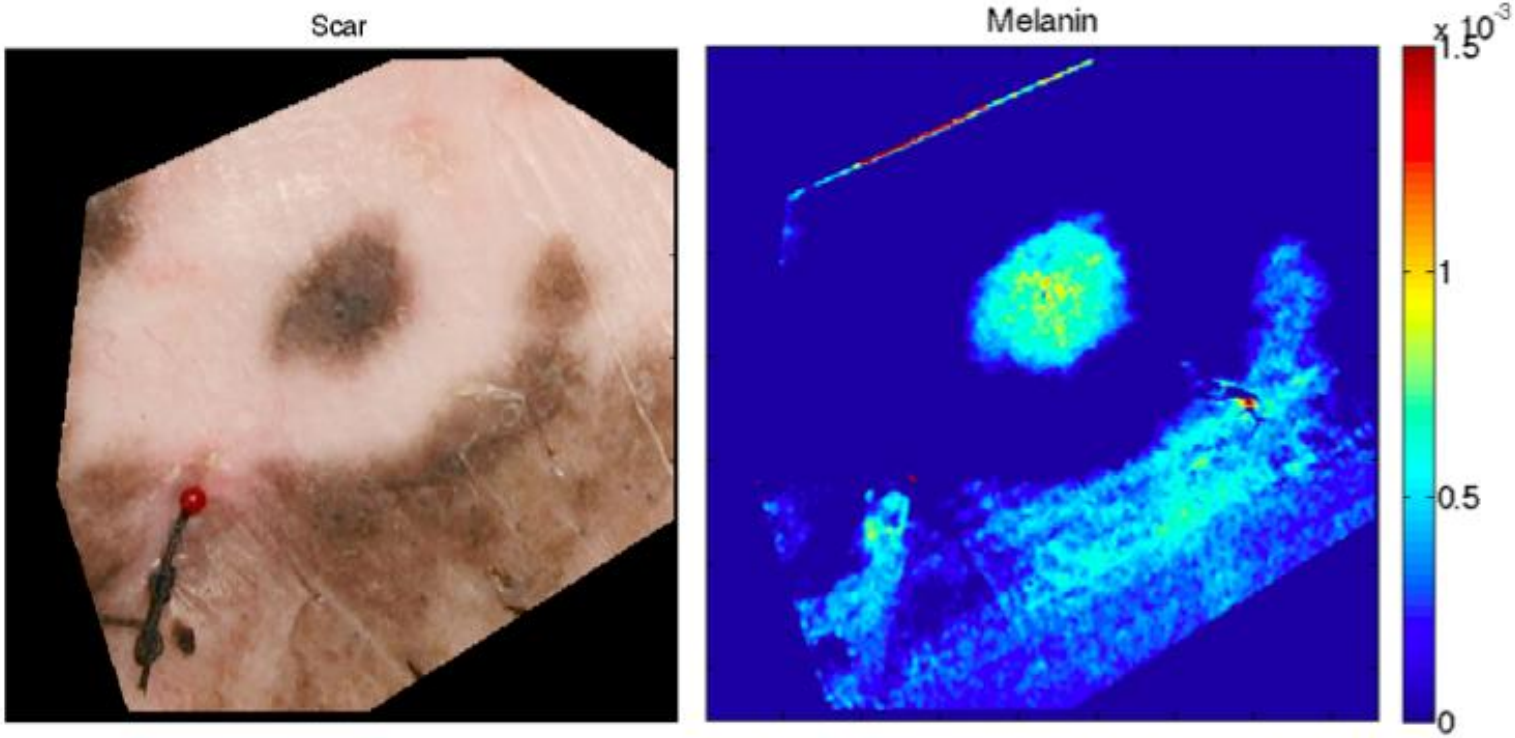

μa _ tot **=** Vblood (S**μ**a _ oxy **+ (**1 - S**)μ**a _ deoxy **)+**W**μ**a _ water **+** M**μ**a _ melanin

MedStar Washington Hospital Center

The Burn Center
MedStar Health

Firefighters' Burn and Surgical Research Laboratory

Spectral Imaging

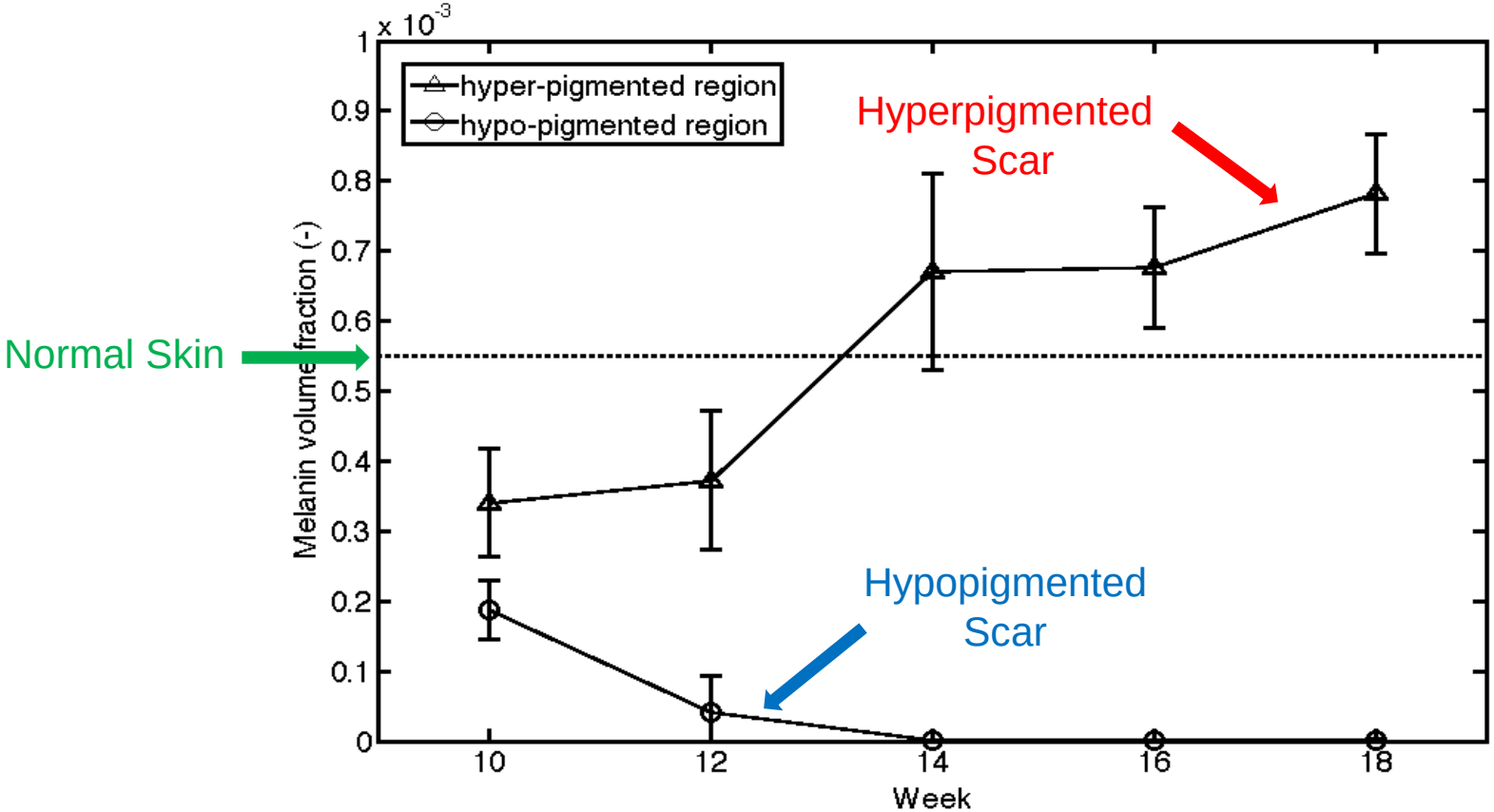

MedStar Washington Hospital Center

The Burn Center
MedStar Health

Firefighters' Burn and Surgical Research Laboratory

Melanocyte Quantity

S-100 Staining

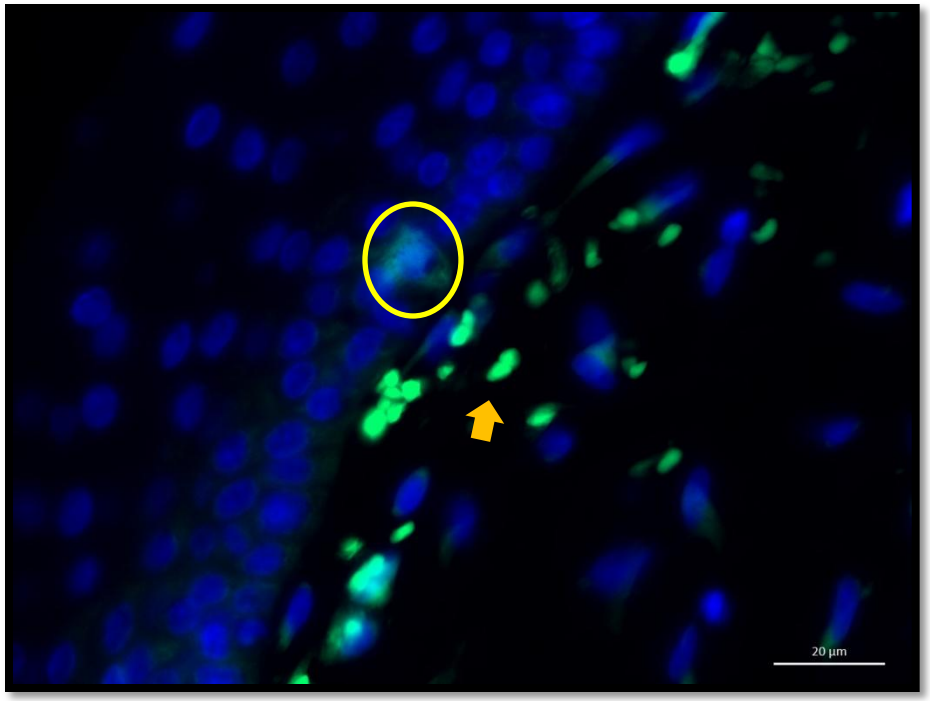

Hypopigmented Scar

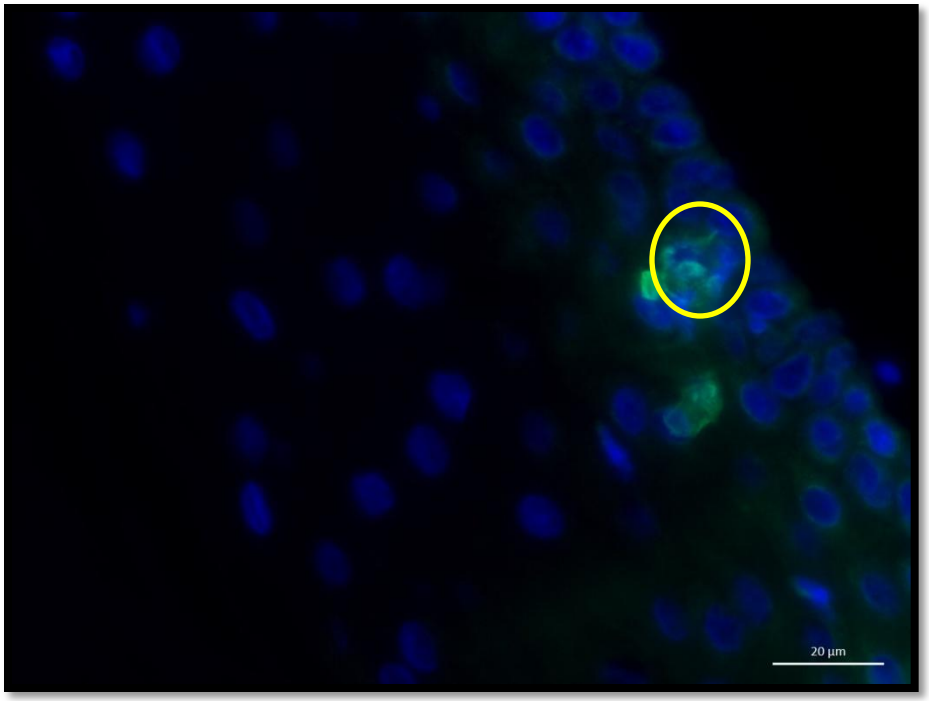

Hyperpigmented Scar

MedStar Washington Hospital Center

The Burn Center
MedStar Health

Firefighters' Burn and Surgical Research Laboratory

Melanocyte Quantity

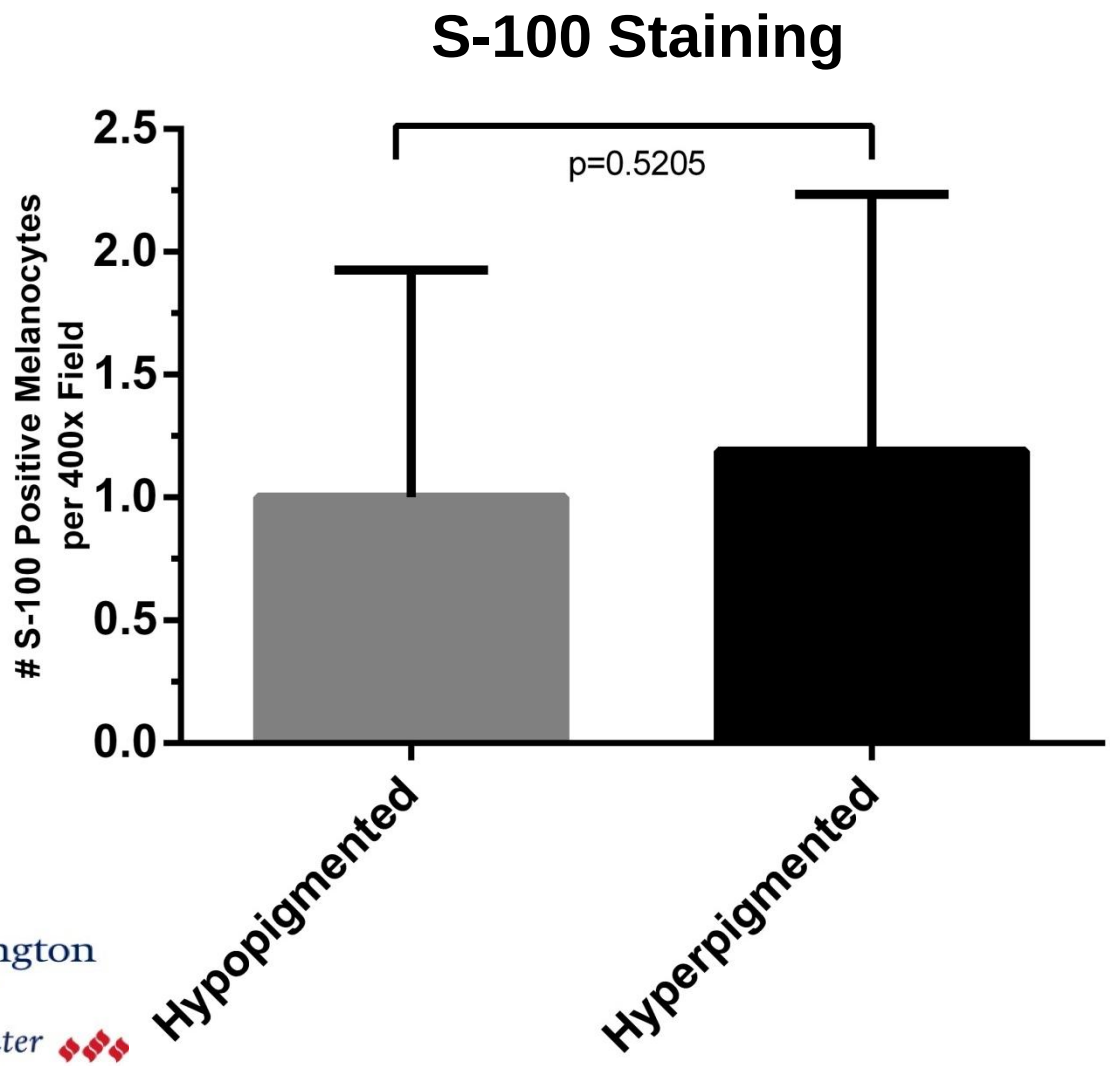

MedStar Washington Hospital Center
The Burn Center
MedStar Health

Firefighters' Burn and Surgical Research Laboratory

Melanin Quantity

Azure B Staining

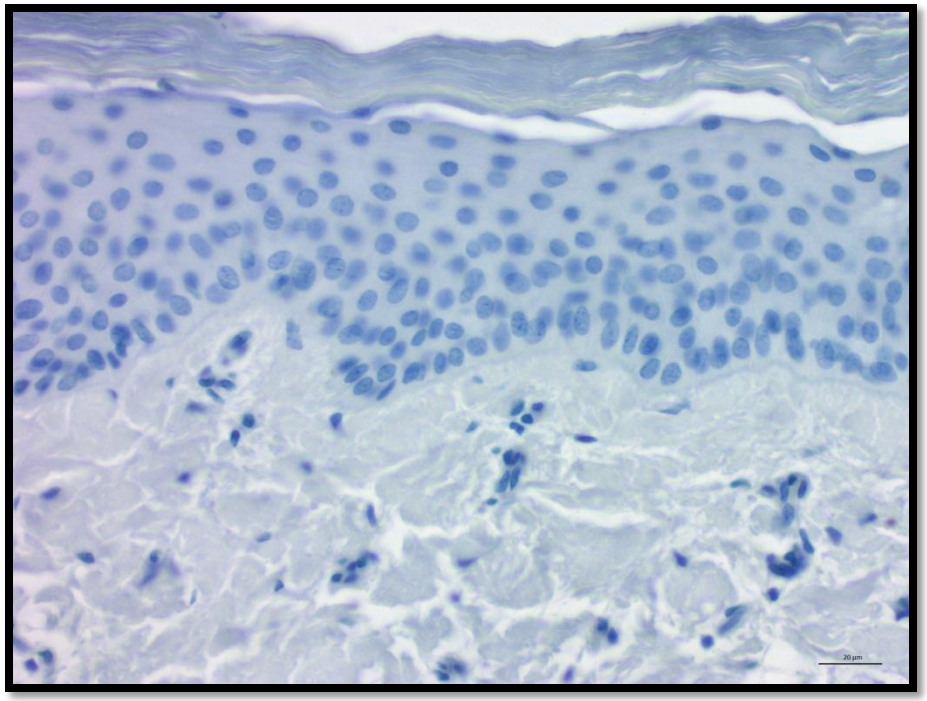

Hypopigmented Scar

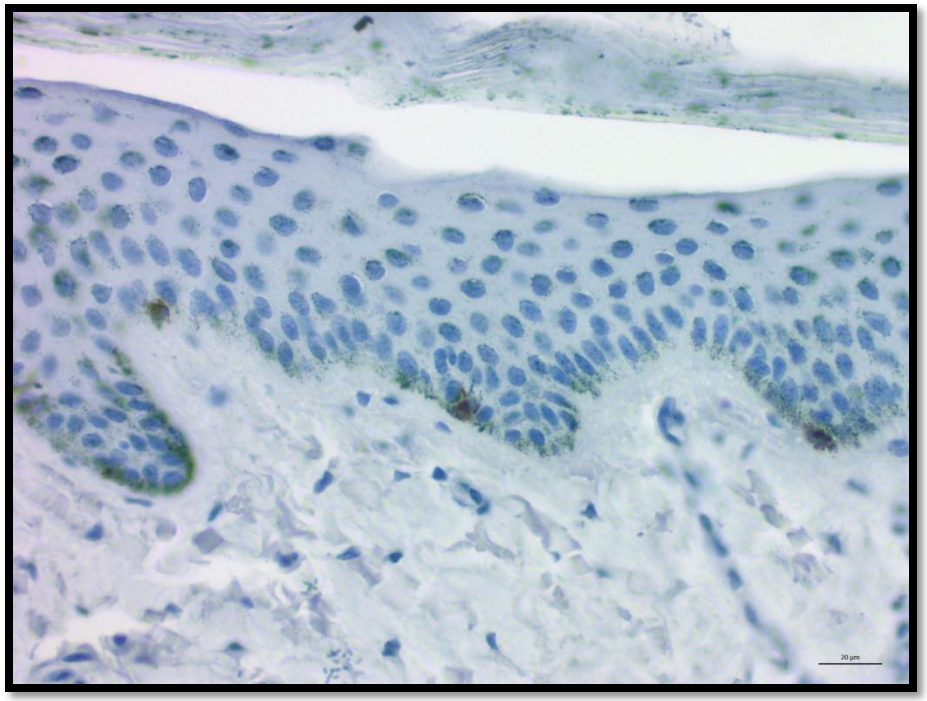

Hyperpigmented Scar

MedStar Washington Hospital Center

The Burn Center
MedStar Health

Firefighters' Burn and Surgical Research Laboratory

Melanin Quantity

Azure B Staining

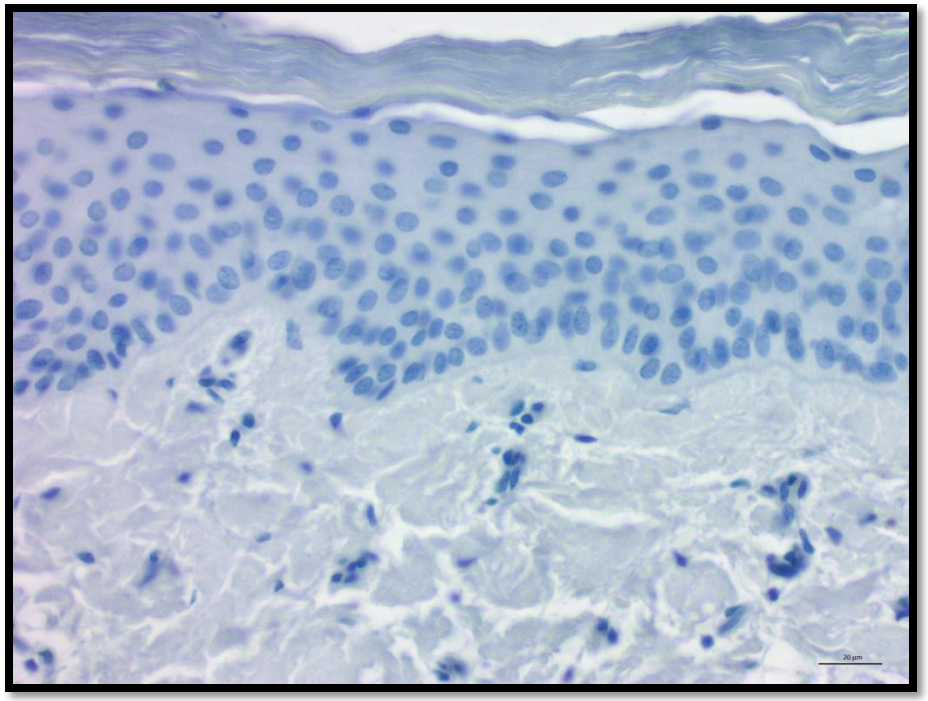

Hypopigmented Scar

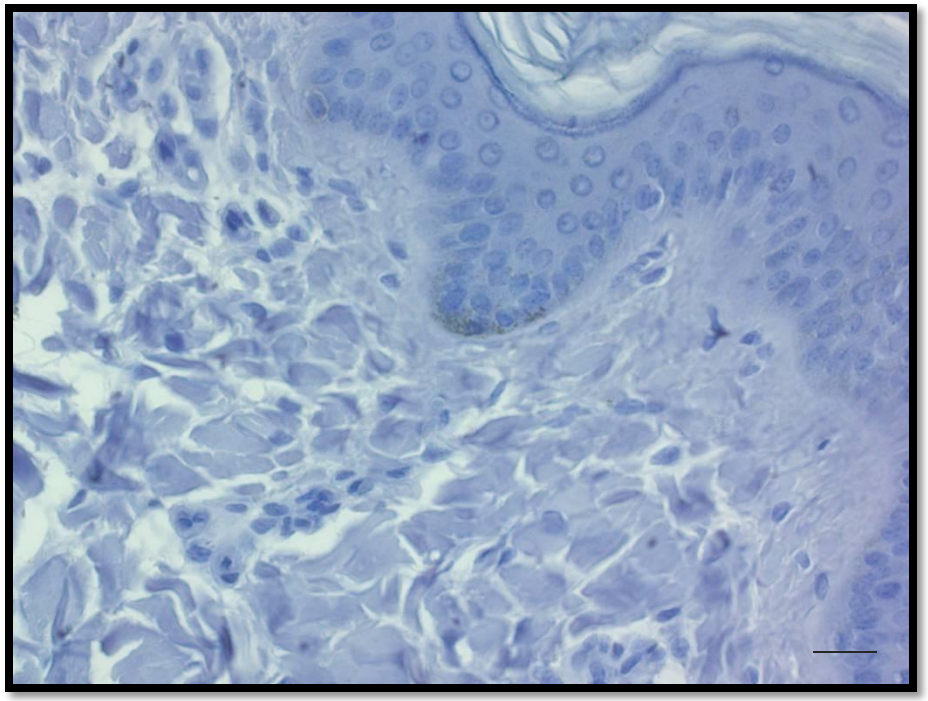

Uninjured Skin

MedStar Washington Hospital Center

The Burn Center
MedStar Health

Firefighters' Burn and Surgical Research Laboratory

Melanin Quantity

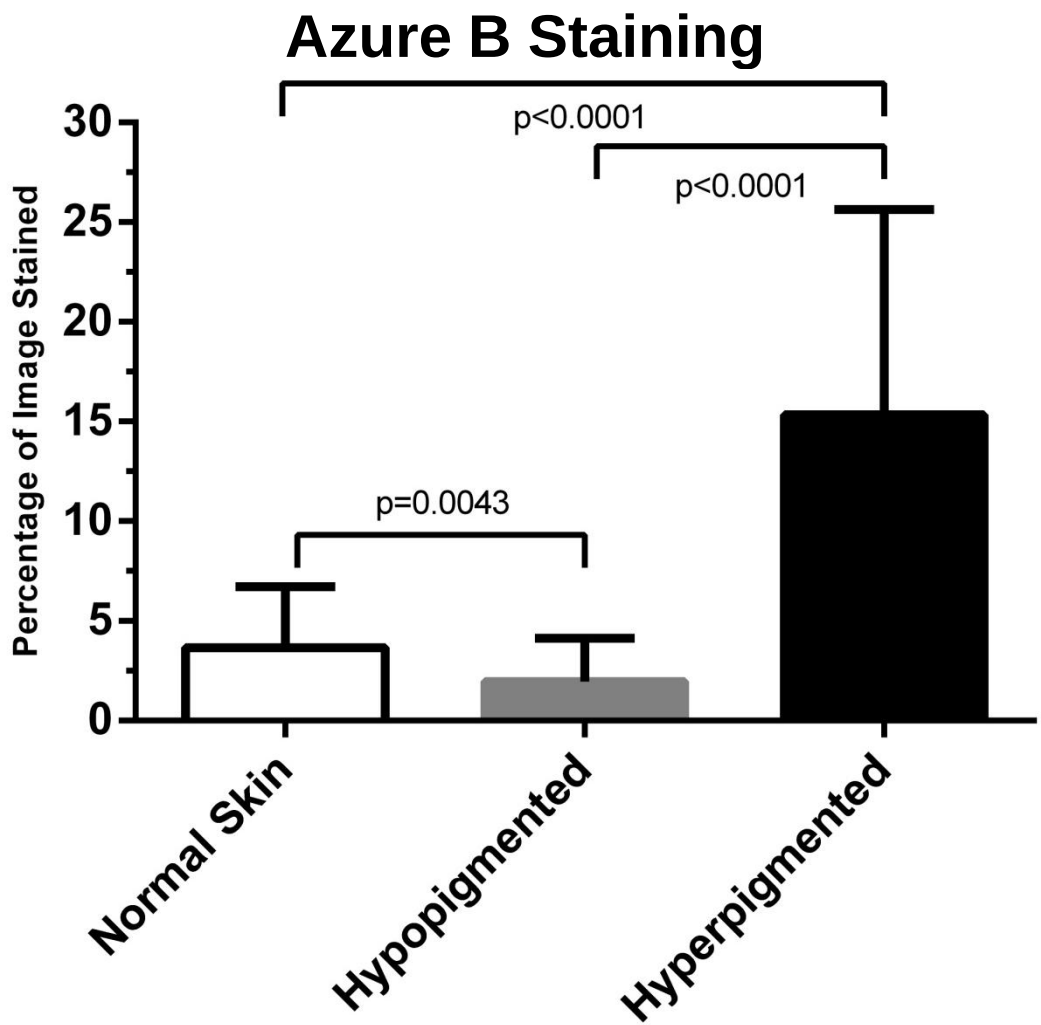

MedStar Washington Hospital Center
The Burn Center
MedStar Health

Firefighters' Burn and Surgical Research Laboratory

Stimulated Melanocytes

HMB-45 Staining

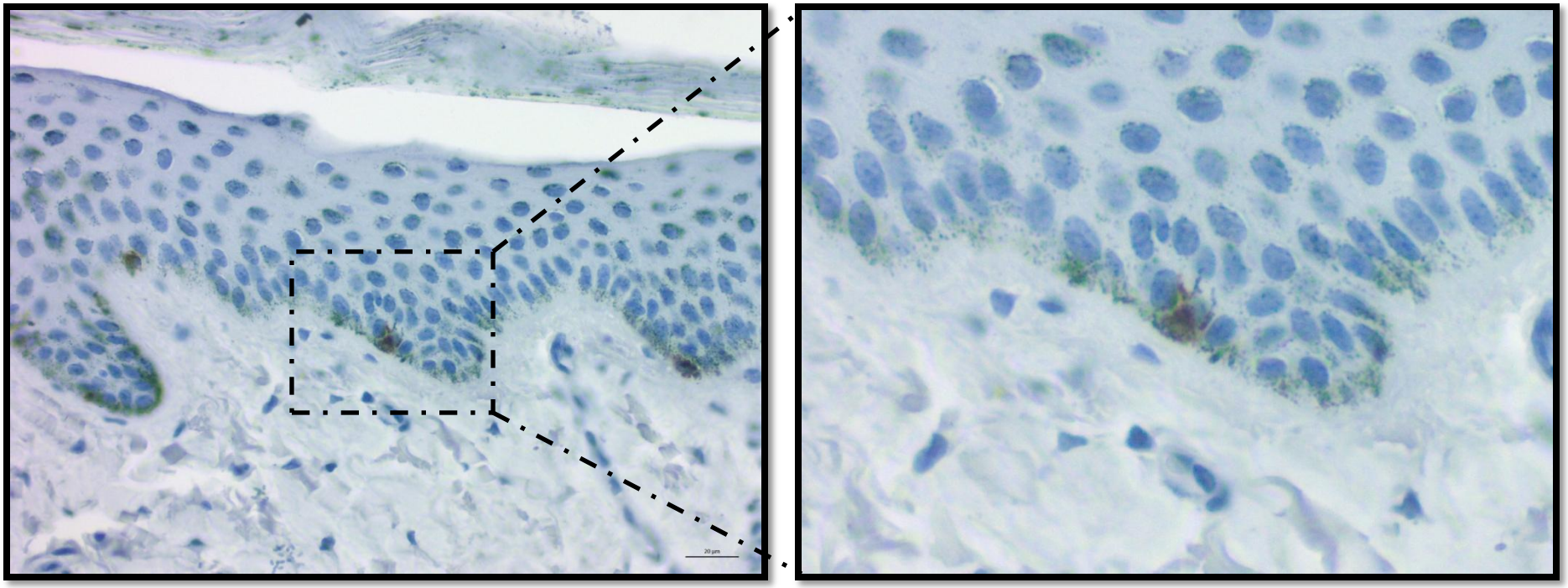

Hyperpigmented Scar

Hyperpigmented Scar

MedStar Washington Hospital Center

The Burn Center
MedStar Health

Firefighters' Burn and Surgical Research Laboratory

Melanocyte Stimulating Hormone

α-MSH Staining

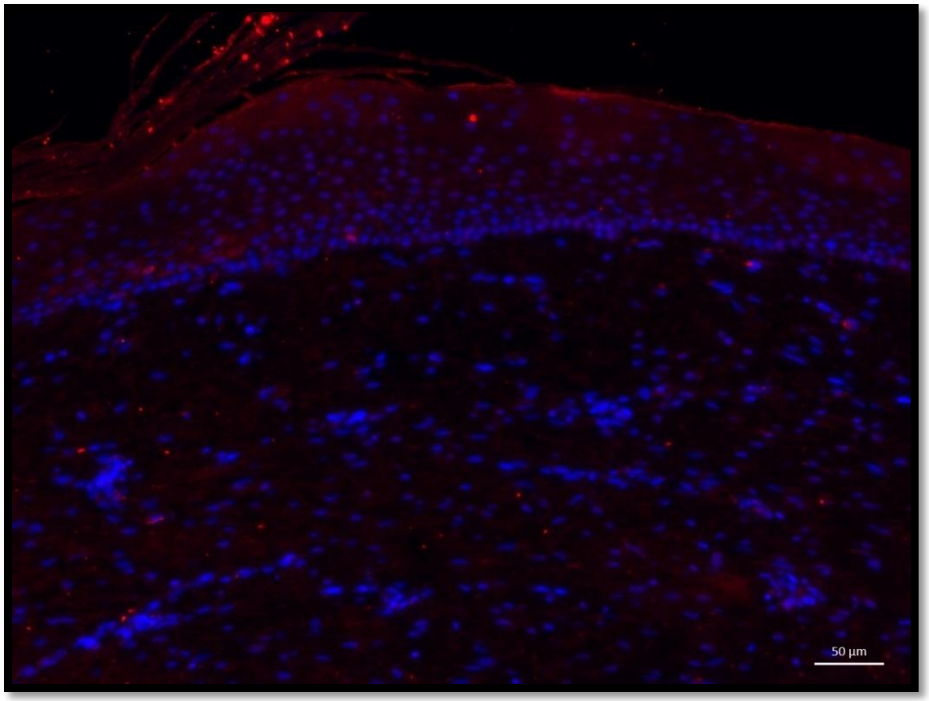

Hypopigmented Scar

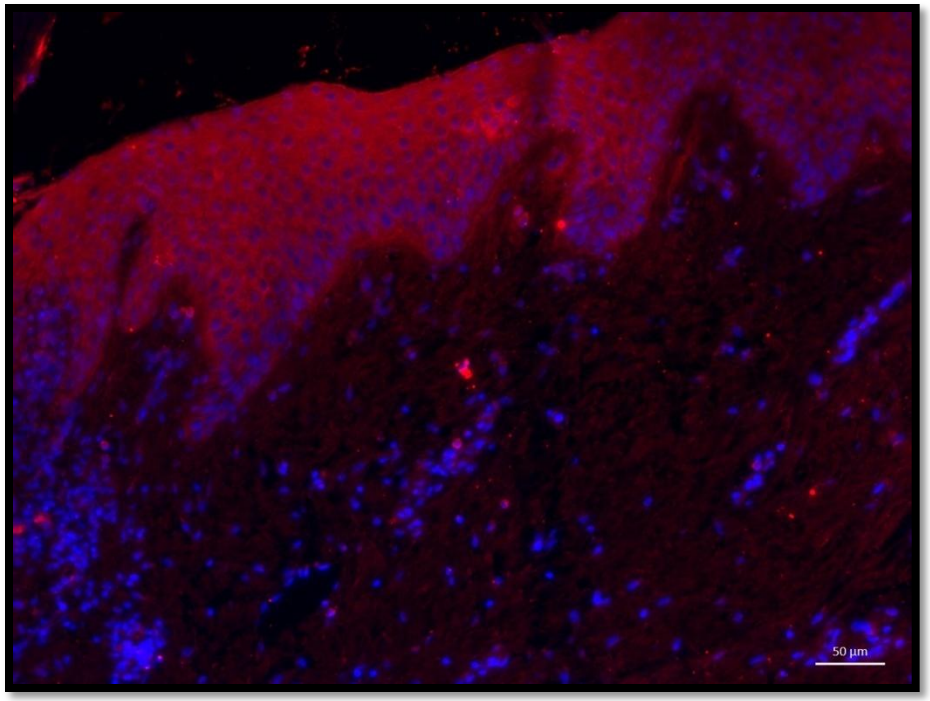

Hyperpigmented Scar

MedStar Washington Hospital Center

The Burn Center
MedStar Health

Firefighters' Burn and Surgical Research Laboratory

Melanocyte Stimulating Hormone

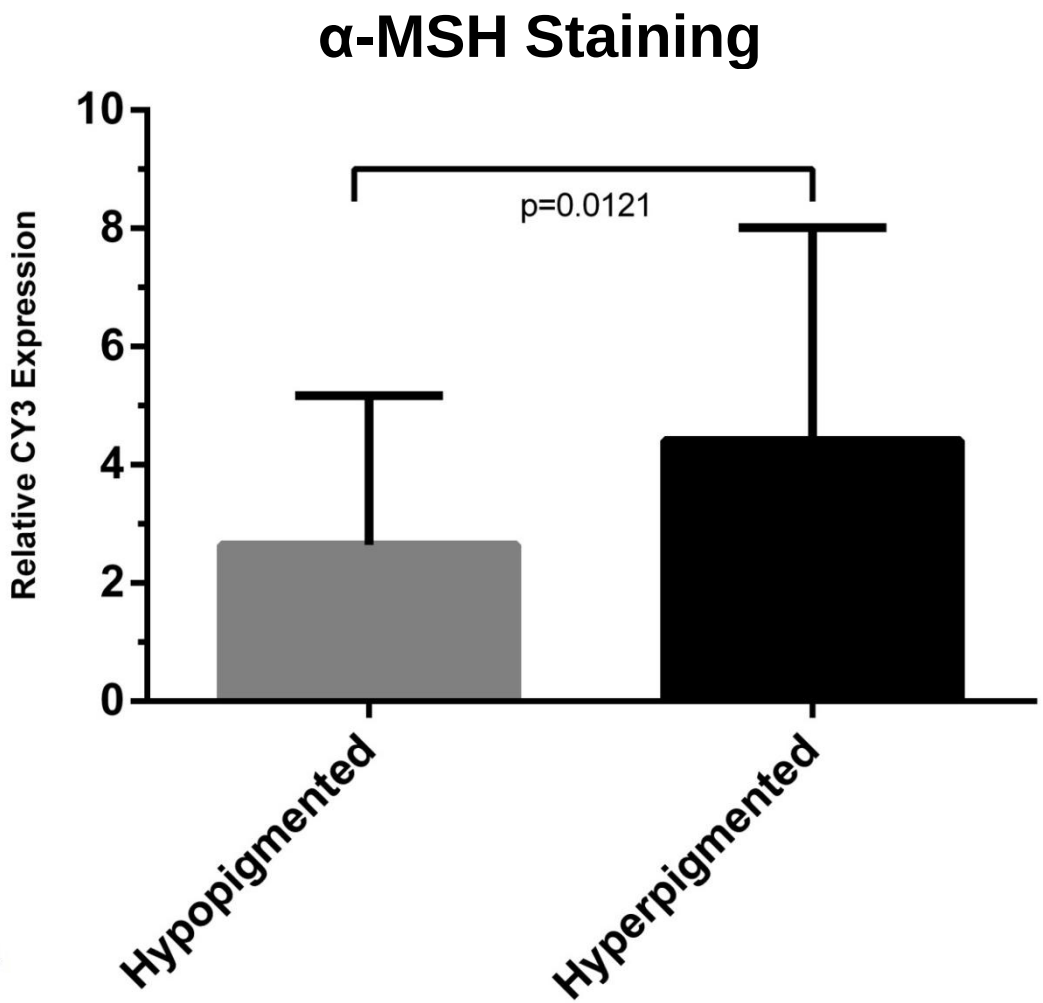

MedStar Washington Hospital Center
The Burn Center
MedStar Health

Firefighters' Burn and Surgical Research Laboratory

Repigmentation from Follicles

- Melanocyte stem cells in follicle bulge areas
- Differentiated melanocytes form melanin on migration to hair bulbs or surrounding epidermis
- Epithelialization and repigmentation increase radially

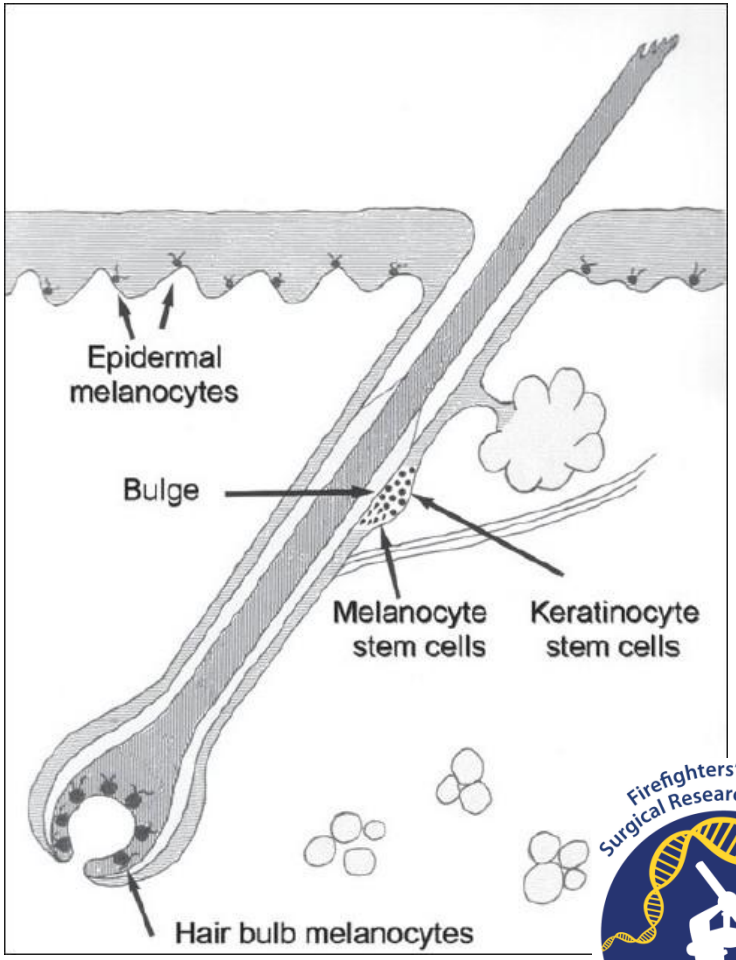

From: Falabella R – Indian J Dermatology 2009

MedStar Washington Hospital Center
The Burn Center
MedStar Health

Firefighters' Burn and Surgical Research Laboratory

Pigmentation in Experimental Scars

- Repigmentation associated spatially with uninjured skin and follicles

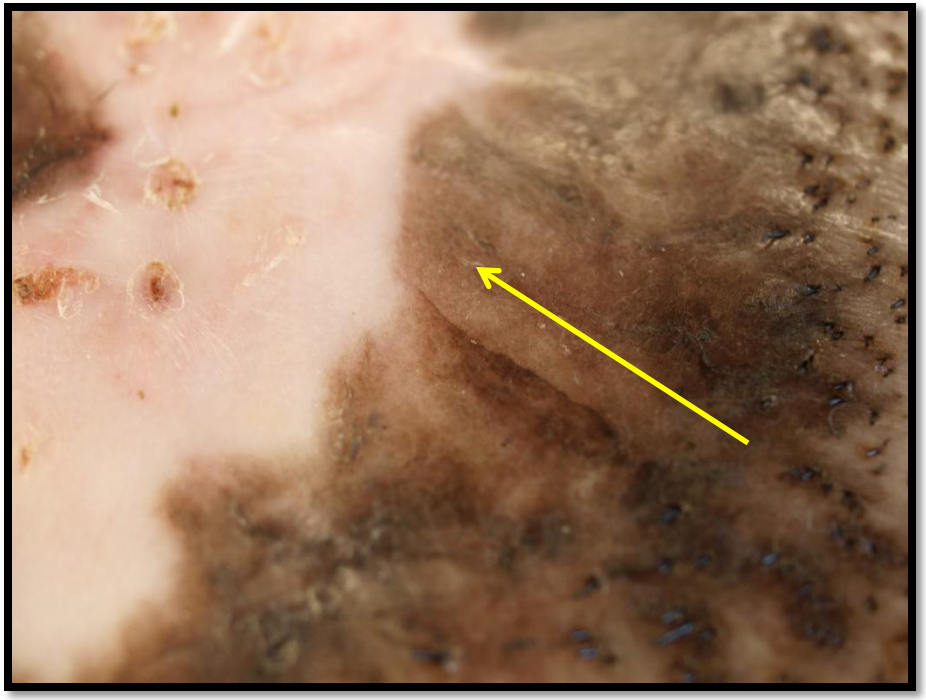

MedStar Washington Hospital Center
The Burn Center
MedStar Health

Firefighters' Burn and Surgical Research Laboratory

Pigmentation in Experimental Scars

- Repigmentation associated spatially with uninjured skin and follicles
- Hypopigmented areas may be explained by destruction of hair follicles

MedStar Washington Hospital Center
The Burn Center
MedStar Health

Firefighters' Burn and Surgical Research Laboratory

Pigmentation in Experimental Scars

- Intensity of hyperpigmentation
  - Darker than pre-injury
  - Increased melanin on histology

MedStar Washington Hospital Center
The Burn Center
MedStar Health

Firefighters' Burn and Surgical Research Laboratory

Pigmentation in Experimental Scars

- Intensity of hyperpigmentation
  - Darker than pre-injury
  - Increased melanin on histology
- Isolated islands surrounded by hypopigmentation
  - Lighter than pre-injury
  - Decreased melanin on histology

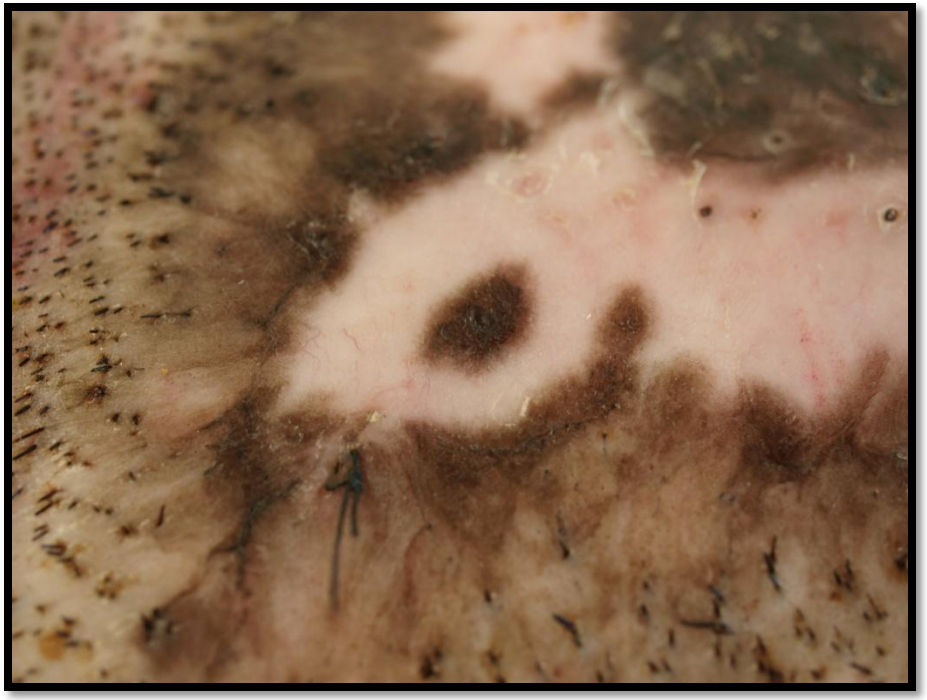

MedStar Washington Hospital Center
The Burn Center
MedStar Health

Firefighters' Burn and Surgical Research Laboratory

Stimulated Melanocytes

- No difference in strict melanocyte number
- Differences in apparent activity of those melanocytes
- What is the role of inflammation?

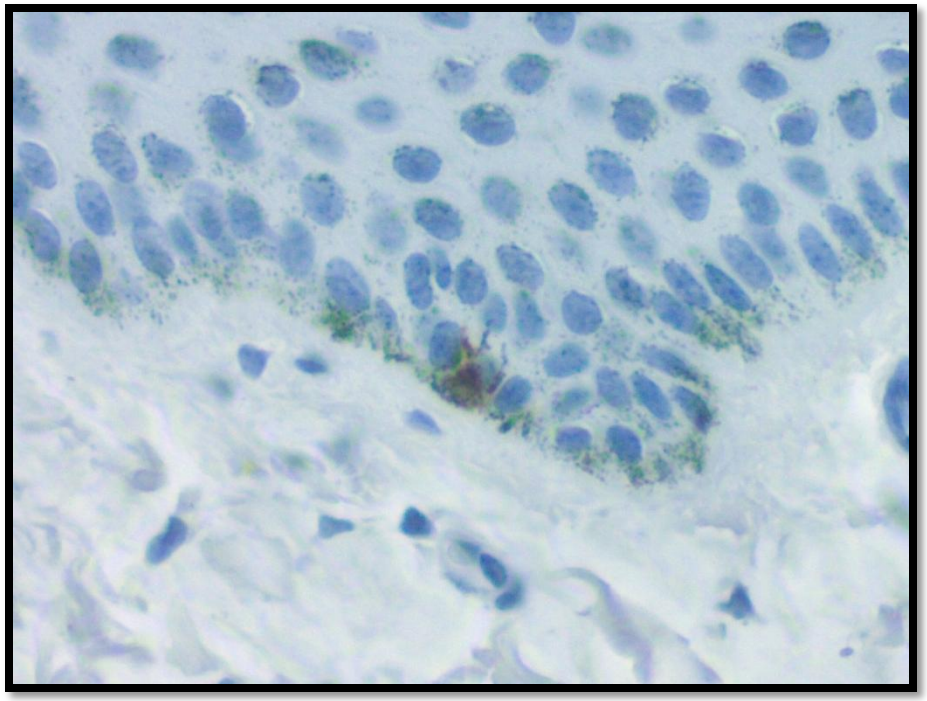

MedStar Washington Hospital Center
The Burn Center
MedStar Health

Firefighters' Burn and Surgical Research Laboratory

Pigmentation and Inflammation

- Inflammation may stimulate increased melanin production
  - As in UV-radiation damage
- Stimulated melanocytes release inflammatory mediators

MedStar Washington Hospital Center
The Burn Center
MedStar Health

Firefighters' Burn and Surgical Research Laboratory

Pigmentation and Inflammation

- Inflammation may stimulate increased melanin production
  - As in UV-radiation damage
- Stimulated melanocytes release inflammatory mediators
- Melanocyte-stimulating hormone acts on melanocortin-1 receptor
- MC1R/α-MSH signaling pathway contributes to ECM and inflammation regulation

MedStar Washington Hospital Center
The Burn Center
MedStar Health

Firefighters' Burn and Surgical Research Laboratory

Next Directions

- Inflammation certainly present
  - How did it influence pigmentation?
- Can SFDI predict areas of abnormal pigmentation early on in healing?
- Is there potential for therapeutic intervention?

MedStar Washington Hospital Center
The Burn Center
MedStar Health

Firefighters' Burn and Surgical Research Laboratory

Conclusions

- In a red Duroc model of hypertrophic scar formation:
  - Melanocyte quantity does not appear to influence pigmentation
  - The production of melanin correlates with hyper and hypopigmentation of scars
  - Hyperpigmented scars appear to contain activated melanocytes
    - HMB45 positivity
    - Increased levels of α-MSH
    - Increased melanin quantity histologically and optically
  - SFDI can be used to identify areas of increased and decreased melanin content

MedStar Washington Hospital Center

The Burn Center
MedStar Health

Firefighters' Burn and Surgical Research Laboratory

Acknowledgements

- American Burn Association
- Funding
  - NIH/NIBIB 1R15EB01343901
  - DC Firefighters' Burn Foundation
- Mentors
  - Jeffrey Shupp, MD
  - Lauren Moffatt, PhD
  - Marion Jordan, MD, FACS
- Colleagues of Firefighters' Burn and Surgical Research Laboratory
  - Nick Prindeze, BS
  - Dereck Paul, BS

MedStar Washington Hospital Center

The Burn Center
MedStar Health

Firefighters' Burn and Surgical Research Laboratory